

# TECHNIQUE CLINIC

## A Modified Transpalatal Arch for Intrusion of Second Molars

**E**xtruded upper second molars are often encountered in adult patients in association with impaired masticatory function and TMD.<sup>1</sup> This article illustrates a technique for second-molar intrusion with a unilateral intrusion arm, based on Kucher and Weiland's design of a transpalatal arch (TPA) for reducing the prominence of a palatal cusp.<sup>2</sup>

### Procedure

A 26-year-old female presented with a missing mandibular right second molar and an extruded maxillary right second molar, along with mild upper and lower anterior crowding (A). The treatment plan called for maxillary second molar intrusion in preparation for a lower second-molar implant.

Brackets were bonded in both arches, and the upper molars were banded. The upper right first molar band included a soldered attachment for a removable palatal bar. A preformed palatal bar was cut in half, and an open helix was bent into one arm, parallel to the palate. On the study cast, the angle of the arm was adjusted to 60-90° so that the helix lay at the height of the center of resistance of the extruded molar.

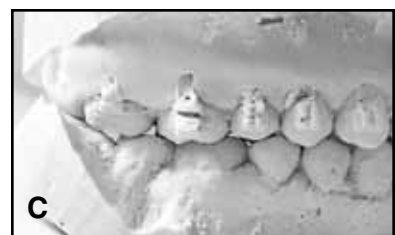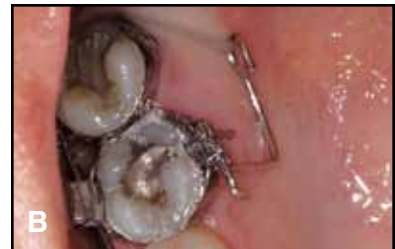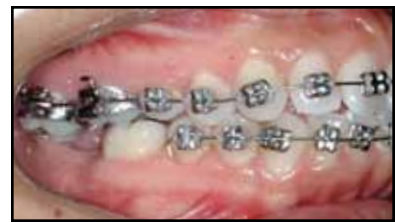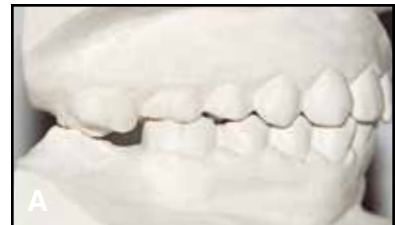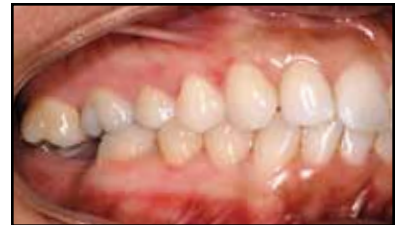A guiding archwire was placed in the upper brackets and

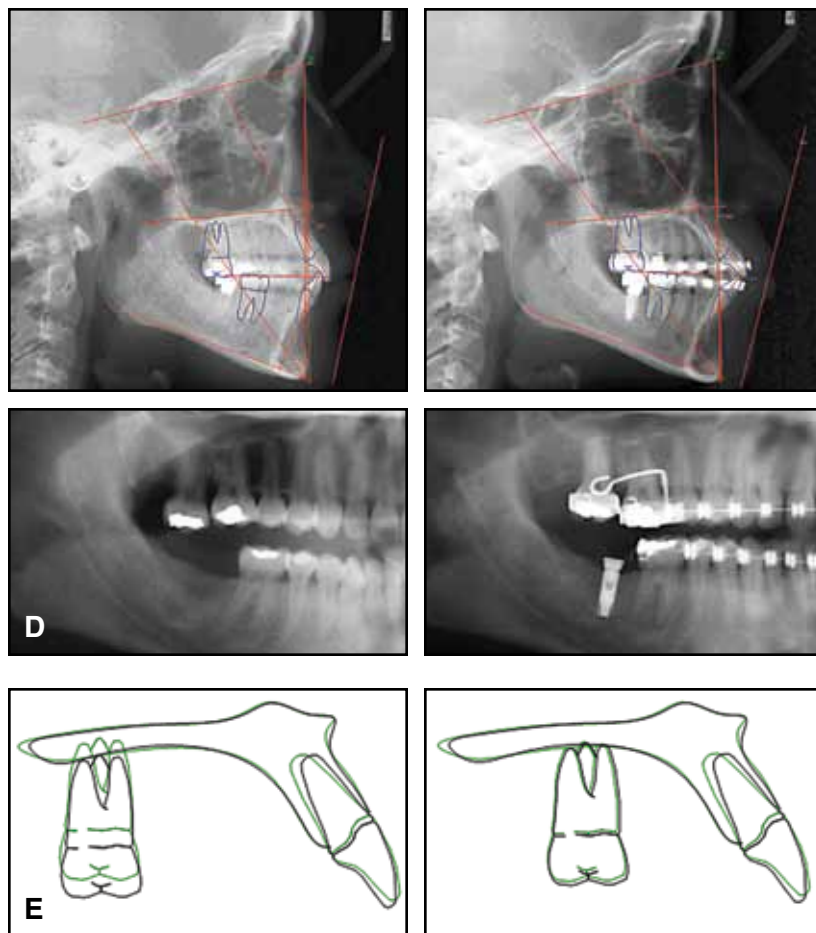
buccal molar tubes, and the modified palatal bar was inserted into the lingual molar attachment (B). To activate the intrusion arm, elastomeric power chain was attached to the palatal sheath of the maxillary right second molar, then looped through the helix of the intrusion arm and back to the sheath. The buccal guiding wire balanced the force of the power chain to create an equilibrium between buccal and palatal root torque, resulting in an intrusive force combined with slight distal and palatal crown tipping.

During intrusion, the height of the helix became more incisal, creating a couple that moved the center of rotation from infinity toward the tooth. If this couple were large enough relative to the forces, the amount of translation would become negligible in comparison to the tipping, and the center of rotation would be near the center of resistance.

The power chain was replaced every three weeks. Sufficient intrusion of the maxillary second molar for implant placement was obtained within two months, requiring only three appointments (C). The surrounding gingival tissues and bony structures remained healthy.

The pretreatment and post-implant cephalometric and panoramic radiographs (D) and regional





superimpositions (E) demonstrated 3.5mm of second-molar intrusion, with no measurable extrusion of the adjacent, anchoring first molar. Moon and colleagues showed similar molar intrusion over the same time period using corticotomy and skeletal anchorage.<sup>3</sup> In our patient, the lack of anchorage loss at the first molar may be attributed to occlusal forces, the stabilizing effect of the buccal guiding archwire, and the use of light forces over an extended period of time.<sup>4</sup>

The extruded tooth was re-

tained for six months with a wraparound retainer to allow restructuring of the periodontal ligament fibers.

## Conclusion

This modified TPA intrusion arm is a clinically elegant, noninvasive, and cost-effective alternative to traditional edgewise mechanics, temporary anchorage devices, and removable appliances. It can be quickly fabricated at chairside and inserted in a single appointment.

## REFERENCES

1. Lyka, I.; Carlsson, G.E.; Wedel, A.; and Kiliaridis, S.: Dentists' perception of risks for molars without antagonists. A questionnaire study of dentists in Sweden, *Swed. Dent. J.* 25:67-73, 2001.
2. Kucher, G. and Weiland, F.J.: Goal-oriented positioning of upper second molars using the palatal intrusion technique, *Am. J. Orthod.* 110:466-468, 1996.
3. Moon, C.H.; Wee, J.U.; and Lee, H.S.: Intrusion of overerupted molars by corticotomy and orthodontic skeletal anchorage, *Angle Orthod.* 77:1119-1125, 2007.
4. Thurow, R.C.: Tissue adaptation to functional and orthodontic stresses, in *Edgewise Orthodontics*, ed. R.C. Thurow and E. Marill, Mosby, St. Louis, 2001, pp. 91-106.



JULIA E. VLACHOJANNIS,  
DMD, MSC  
Lofou 4A Ekali  
Athens 14578  
Greece  
julia@vlachojannis.com



MARGHERITA SANTORO,  
DDS, MA  
Division of Orthodontics  
Columbia University  
School of Dental and Oral Surgery  
New York, NY